

Editorial Review

HIV-associated nephropathy: a diagnosis in evolution

Patricio E. Ray^{1,2}

¹Research Center for Molecular Physiology, Division of Nephrology, Children's National Medical Center, Washington, DC, USA and ²Department of Pediatrics, The George Washington University, Washington, DC, USA

Correspondence and offprint requests to: Patricio E. Ray; E-mail: Pray@cnmc.org

Abstract

HIV-1 associated nephropathy (HIVAN) is a clinical and renal histological disease characterized by the presence of heavy proteinuria associated with focal segmental glomerulosclerosis and microcystic tubular dilatation. These renal lesions lead to renal enlargement and rapid progression to kidney failure. People from African ancestry show a unique susceptibility to develop HIVAN. The study by Wearne and colleagues, which includes the largest group of patients of African ancestry with HIVAN studied so far, describes a novel renal histological variant of HIVAN, and suggests that antiretroviral therapies improve the clinical outcome of all HIV-associated renal diseases. These findings, when interpreted in the context of recent advances in our understanding of the molecular pathogenesis and genetics of HIVAN, will facilitate the recognition of all clinical variants of HIVAN as well the planning of better screening, prevention, and treatment programs for all HIV nephropathies.

Keywords: APOL-1; collapsing glomerulopathy; FSGS; HIV-1

Since the beginning of the acquired immunodeficiency syndrome (AIDS) epidemic almost 30 years ago, many renal diseases that affect the outcome of HIV-infected patients have been described [1–3]. Among them, HIV-associated nephropathy (HIVAN) received significant attention because of the rapid development of irreversible chronic renal failure in African American patients with AIDS [1, 2]. Despite the remarkable medical advances made in our understanding and treatment of HIVAN, several important issues remained unresolved. Surprisingly, there is still lack of consensus regarding the definition of HIVAN. This issue can affect our ability to design appropriate clinical trials or explore the pathogenesis of this disease. The study by Wearne *et al.*, published in this issue of *Nephrology Dialysis Transplantation* provides valuable clinical information regarding the renal histological lesions associated with HIV-1 infection [4]. This study, which includes the largest group of patients of African ancestry with HIVAN studied so far, also describes a novel renal histological variant of HIVAN and

suggests that antiretroviral therapies improve the clinical outcome of all HIV renal diseases. Therefore, to assess the clinical relevance of these findings, it is worth reviewing the history of HIVAN in the context of the most recent medical advances.

In 1984, HIVAN was identified in patients with AIDS in New York and Miami [1, 2]. Initially, it was named AIDS-associated nephropathy, but this name was changed to HIVAN when asymptomatic HIV-infected individuals showed similar clinical and renal histological features. In the early stages of the AIDS epidemic, patients with HIVAN typically presented with severe nephrotic syndrome and renal insufficiency. They frequently showed profound hypoalbuminaemia, with minimal or absent peripheral oedema and hypertension and a very rapid progression to end-stage renal disease (ESRD) [1, 2]. Their renal histology revealed global or focal segmental glomerulosclerosis (FSGS), often in different stages of evolution, prominent degenerative and hypertrophic changes in visceral epithelial cells, mesangial deposits of complement (C3), IgM and sometimes IgG, but not IgA, microcystic tubular dilatation containing large plasma proteins, interstitial oedema and tubuloreticular inclusions (TRI) in glomerular and peritubular endothelial cells [1, 2]. The mesangial deposits were considered non-specific because they were detected in patients with AIDS who had normal glomeruli and in HIV-negative patients with hypertension or diabetes [3]. Interestingly, the renal histological features recognized years later as 'collapsing glomerulopathy' were not mentioned in the initial reports. Moreover, these studies concluded that the renal histological lesions of HIVAN were indistinguishable from heroin-associated nephropathy (HAN) or idiopathic FSGS [1, 2]. However, kidneys with HIVAN showed normal or enlarged size, in contrast to the small fibrotic kidneys seen in ESRD of other aetiologies [3]. In summary, the most distinctive features of HIVAN were the clinical symptoms, its predilection for African American individuals and the renal enlargement.

In the late 1980s, HIVAN was detected in children who acquired HIV-1 through vertical transmission [3, 5]. These findings provided compelling evidence for the existence of an HIV-related glomerulopathy that could

evolve independently of intravenous drug use [3, 5]. Years later, many studies confirmed that the incidence of HIVAN could be reduced in a significant manner by decreasing the HIV-1 viral load [6, 7]. It is worth mentioning here that some HIV-infected children developed a childhood variant of HIVAN characterized by proteinuria, in combination with mesangial hyperplasia and microcystic tubular dilatation [3, 5, 8]. Because at that time mesangial expansion and hyperplasia were considered the initial events leading to FSGS in several renal diseases, these findings were interpreted as the early stages of HIVAN [3, 5]. In support of this notion, an extensive review of 159 renal biopsies and autopsies done in Miami revealed a high incidence of glomerular mesangial hyperplasia in the AIDS population [3]. In addition, this study found a spectrum of renal glomerular lesions ranging from focal and diffuse mesangial hyperplasia with minor FSGS changes to global glomerulosclerosis [3]. Once again the microcystic changes were considered, the most consistent renal findings in HIVAN and subsequent studies done in transgenic (Tg) mice confirmed that these lesions were responsible for the renal enlargement [7].

In 1986, renal biopsies in six patients who develop nephrotic syndrome and rapid ESRD revealed a remarkable collapse of the glomerular capillary loops, such as might occur with glomerular hypoperfusion [9]. These changes were associated with tubulointerstitial lesions similar to HIVAN. One of these patients subsequently developed AIDS, but the other five patients remained HIV-negative. This 'malignant' form of idiopathic FSGS was named 'collapsing glomerulopathy' (CG) and considered a new renal entity [9]. Soon, CG was recognized in patients with HIVAN. For example, a review of the renal biopsies done at Columbia University in New York highlighted the collapsing global pattern of glomerulosclerosis seen in HIVAN and proposed to use the term 'diffuse sclerosis glomerulopathy', instead of FSGS, to describe these lesions [10]. Moreover, the collapse of glomerular capillaries, in the absence of endocapillary foam cells or glomerular hyalinosis, was considered an earlier morphological feature of HIVAN that could progress to a non-specific pattern of 'global glomerulosclerosis'. According to this interpretation, the collapsing feature could disappear during the late stages of HIVAN [10]. However, when the HIVAN samples were compared with HAN or idiopathic FSGS, no single pathological feature was considered in itself specific for HIVAN [10], as reported in the original studies [1, 2]. Nevertheless, the diffuse collapsing global pattern described above became a distinctive feature of HIVAN.

In 2004, the Columbia classification of FSGS reviewed the histological definition of CG [11]. The new definition required only the collapse of at least one capillary loop, with obliteration of the lumen, in one glomerulus, in addition to hypertrophic or hyperplastic podocytes overlying the collapsed capillaries, regardless of the presence of other variants of FSGS or tubulointerstitial lesions [11]. Subsequently, using this new definition, the number of CG cases associated with other renal diseases increased in an exponential manner, and the CG patterns became a less 'distinctive' feature of HIVAN. For example, the CG

phenotype is absent in ~57% of the HIVAN cases described by Wearne *et al.* [4] and a higher number of children with HIVAN described in other studies [3, 5, 8]. More recently, a new taxonomy for 'podocytopathies' was developed based on the assessment of glomerular morphology/podocyte phenotype and aetiology [12]. This new taxonomy considered CG a different entity apart from FSGS [12]. According to this nomenclature, HIV-1 could induce at least three different 'podocytopathies', including FSGS, CG and diffuse mesangial sclerosis, if the foetal variant described by Wearne *et al.* is included in the last group. In an ideal taxonomy, however, patients should progress through various stages of one disease or podocytopathy; instead, HIVAN appears to progress through one podocytopathy to another. In addition, another point to discuss is whether HIVAN should be considered a primary podocytopathy. Many systemic and intrinsic renal cells, in addition to podocytes, play a key role in the pathogenesis of HIVAN. For example, to gain access to podocytes and tubular epithelial cells, HIV-1 should 'go through' glomerular and peritubular endothelial cells, usually by Trojan horse-like mechanism inside inflammatory cells [7]. The TRI found in glomerular and peritubular endothelial cells suggest that these renal structures can be affected directly and independently [2, 3]. Moreover, Tg mice that express HIV genes under the control of the human CD4 promoter, which restricts the expression of HIV-1 genes mainly to circulating immune cells, develop FSGS and microcysts [13]. Cytokines released by HIV-infected cells [e.g. interferon (IFN)- α - β or - γ] can precipitate the development of CG in HIV-negative patients [14]. In addition, studies done in humans and HIV-Tg mice show that injured podocytes can be replaced by proliferating parietal epithelial or renal stem cells [15–17]. Alternatively, the 'acute' capillary collapse seen in HIVAN patients with hypoalbuminaemia, generalized oedema and renal failure suggests that renal haemodynamic changes may play an additional role in this process [9]. Finally, the microcystic transformation of renal tubules can occur in the absence of significant podocyte lesions, as seen in the interstitial and childhood variants of HIVAN [4, 7] (Figure 1). Taken together, all these observations highlight the need to reach a consensus regarding the definition of HIVAN, in order to implement better screening, prevention and treatment programmes.

Another interesting finding reported by Wearne *et al.* [4] is the new foetal variant of HIVAN. This renal histological variant resembles the structure of foetal glomeruli and is associated with the worst clinical outcome. These glomeruli show a strikingly dense mesangial sclerotic core with no peripheral loops or collapse. The surface of the inner core is covered by hypertrophied and hyperplastic visceral epithelial cells [4]. Although these lesions could be a CG in evolution, the dense mesangial sclerotic lesions, absence of glomerular collapse and the worse clinical outcome relative to CG suggest that this is an unlikely possibility. Interestingly, Tg mice expressing HIV-1 genes only in podocytes can show immature glomeruli with cuboidal podocytes, mesangial expansion and hyperplasia [18]. As discussed above, both mesangial expansion and hyperplasia are detected in HIV-infected adults,

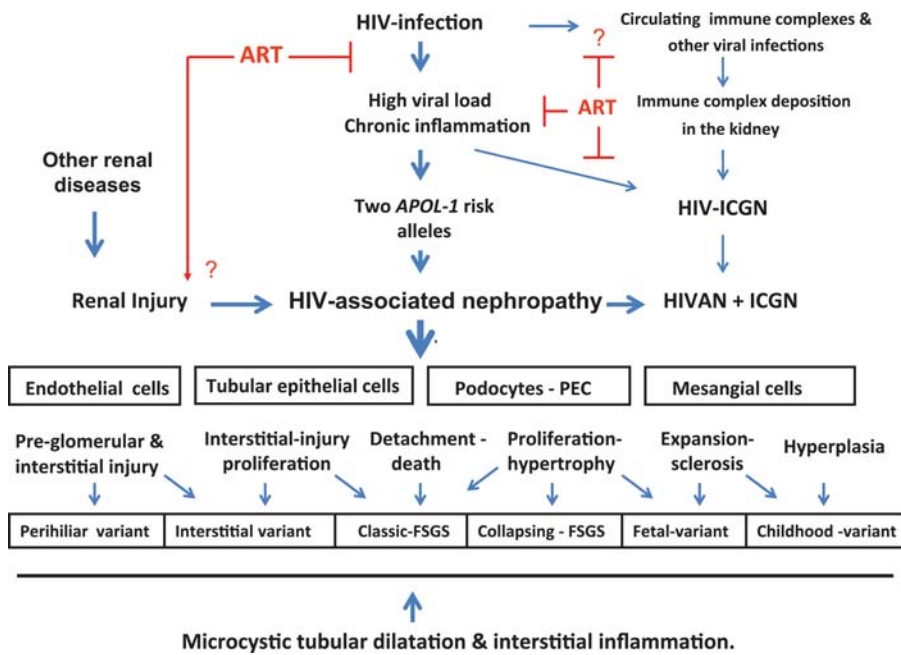


Fig. 1. Risk factors and pathogenesis of HIV-associated renal diseases. A longstanding high viral load is a major risk factor for the development of HIV-associated renal diseases. Immune activation and chronic inflammation are crucial features driving HIV replication and are additional risk factors for the development of HIV-associated renal diseases. Antiretroviral therapies (ART) block HIV-1 replication, decreasing the viral load and the chronic inflammatory changes (red lines). Untreated individuals of African ancestry carrying two risk variants of the *APOL-1* gene are at very high risk of developing HIVAN. The incidence of HIVAN is reduced in a significant manner with ART. These drugs can also induce renal injury *per se* (red arrow). Other renal diseases may affect the clinical outcome of HIVAN. Some individuals develop HIVAN in combination with immune complex glomerulonephritis (HIVAN + ICGN). The *APOL1* risk variants do not appear to play a direct role in the pathogenesis of HIV-associated immune complex glomerulonephritis (HIV-ICGN). HIV-1 affects several intrinsic renal cell types and induces different histological variants of HIVAN. The tubulointerstitial lesions are the most consistent findings seen in patients with HIVAN and can predict an adverse clinical outcome. PEC, parietal epithelial cells; ICGN, immune complex glomerulonephritis.

children and HIV-Tg rats [3, 5, 8, 19]. Previous studies showed that injured podocytes and endothelial cells can release heparin-binding growth factors that induce hyperplasia and expansion of mesangial cells (e.g. fibroblast growth factor-2) [7]. In contrast, healthy podocytes and endothelial cells produce heparan sulphate proteoglycans that have an opposite inhibitory effect [7]. Rats that express the human diphtheria toxin (DT) receptor only in podocytes demonstrate that injured podocytes can lead to mesangial expansion and glomerulosclerosis [20]. A moderate depletion of podocytes (<20%) induced by DT showed mesangial expansion, transient mild proteinuria and normal renal function. A more robust depletion of podocytes (<40%) showed mesangial expansion, FSGS, mild sustained proteinuria and normal renal function. Finally, further podocyte depletion (>40%) showed segmental to global glomerulosclerosis with sustained high-grade proteinuria and reduced renal function [20]. HIV-Tg mice/rats expressing HIV transcripts in podocytes, but not in mesangial cells, also develop different degrees of mesangial expansion and proliferation, depending on the stage of the renal disease [7, 18]. Overall, more studies are needed to determine how HIV-1 induces mesangial injury and to define the pathogenesis of the foetal variant of HIVAN.

Finally, the discovery that two coding sequence variants in the *APOL-1* gene, named G1 and G2, can increase the risk of untreated HIV-infected people to

develop HIVAN by ~50% [21, 22], will probably affect the way we define, classify and study the pathogenesis of all HIV renal diseases. These *APOL-1* risk variants, which are not frequently detected in Europeans or other ethnic groups, encode a secreted lipid-binding protein named apolipoprotein L1 (apoL1) [21, 22]. This protein is lethal to the *Trypanosoma brucei rhodesiense*, a parasite that causes African sleeping sickness [17, 21]. One variant copy of apoL1 appears to provide resistance to this infection, while two variant copies are needed to increase the risk of HIVAN. These findings explain why HIVAN is seen, almost exclusively, in patients of African ancestry, and why blacks from Northeast Africa or Ethiopia, which do not carry the risk variants, do not develop HIVAN [23]. APO1-associated FSGS occurs earlier and progresses to ESRD more rapidly [22, 24]. The mechanisms responsible for the renal effects of the risk variants are not clearly understood. ApoL1 has several roles, including the transport of lipids and cholesterol, formation of ion channels in lipid bilayers, innate immune responses, cytolysis and autophagic cell death [17, 21]. Cytokines released by HIV-1-infected cells (IFN- γ and tumour necrosis factor- α) induce the expression of APO1 in cultured endothelial cells [17]. Moreover, apoL1 is detected in mononuclear cells, podocytes, proximal tubules, renal vascular smooth muscle cells and in medium-sized arterial and arteriolar renal endothelial cells [17, 25]. Although it is unclear whether these findings

represent de novo synthesis or apoL1 uptake from the circulation, the specific kidney domains that show apoL1 expression could potentially affect the outcome of all HIVAN variants described by Wearne *et al.* [4] (Figure 1). More studies are needed, however, to define how apoL1 affects the outcome of HIVAN. As new information becomes available, our understanding of the definition and pathogenesis of HIVAN will continue its evolution. HIVAN may become part of a spectrum of 'APOL1-associated renal diseases' that affect different systemic and intrinsic renal cell types. We hope that this new knowledge will facilitate the planning of better screening, prevention and treatment programmes for all HIV nephropathies.

Acknowledgements. This work was supported by National Institutes of Health grants (R01-DK049419 and R01-HL55605).

Conflict of interest statement. None declared.

(See related article by Wearne *et al.* The spectrum of renal histologies seen in HIV with outcomes, prognostic indicators and clinical correlations. *Nephrol Dial Transplant* 2012; 27: 4109–4118.)

References

- Rao TK, Filippone EJ, Nicastrì AD *et al.* Associated focal and segmental glomerulosclerosis in the acquired immunodeficiency syndrome. *N Engl J Med* 1984; 310: 669–673
- Pardo V, Aldana M, Colton RM *et al.* Glomerular lesions in the acquired immunodeficiency syndrome. *Ann Intern Med* 1984; 101: 429–434
- Pardo V, Meneses R, Ossa L *et al.* AIDS-related glomerulopathy: occurrence in specific risk groups. *Kidney Int* 1987; 31: 1167–1173
- Wearne N, Swanepoel C, Boule A *et al.* The spectrum of renal histologies seen in HIV with outcomes prognostic indicators and clinical correlations. *Nephrol Dial Transplant* 2012; doi:10.1093/ndt/GFR702
- Strauss J, Abitbol C, Zilleruelo G *et al.* Renal disease in children with the acquired immunodeficiency syndrome. *N Engl J Med* 1989; 321: 625–630
- Lucas GM, Eustace JA, Sozio S *et al.* Highly active antiretroviral therapy and the incidence of HIV-1-associated nephropathy: a 12-year cohort study. *AIDS* 2004; 18: 541–546
- Ray PE. Taking a hard look at the pathogenesis of childhood HIV-associated nephropathy. *Pediatr Nephrol* 2009; 24: 2109–2119
- McCulloch MI, Ray PE. Kidney disease in HIV-positive children. *Semin Nephrol* 2008; 28: 585–594
- Weiss MA, Daquioag E, Margolin EG *et al.* Nephrotic syndrome, progressive irreversible renal failure, and glomerular “collapse”: a new clinicopathologic entity? *Am J Kidney Dis* 1986; 7: 20–28
- D'Agati V, Suh JI, Carbone L *et al.* Pathology of HIV-associated nephropathy: a detailed morphologic and comparative study. *Kidney Int* 1989; 35: 1358–1370
- D'Agati VD, Fogo AB, Bruijn JA *et al.* Pathologic classification of focal segmental glomerulosclerosis: a working proposal. *Am J Kidney Dis* 2004; 43: 368–382
- Barisoni L, Schnaper HW, Kopp JB. A proposed taxonomy for the podocytopathies: a reassessment of the primary nephrotic diseases. *Clin J Am Soc Nephrol* 2007; 2: 529–542
- Rahim MM, Chrobak P, Hu C *et al.* Adult AIDS-like disease in a novel inducible human immunodeficiency virus type 1 Nef transgenic mouse model: CD4+ T-cell activation is Nef dependent and can occur in the absence of lymphopenia. *J Virol* 2009; 83: 11830–11846
- Markowitz GS, Nasr SH, Stokes MB *et al.* Treatment with IFN- α , - β , or - γ is associated with collapsing focal segmental glomerulosclerosis. *Clin J Am Soc Nephrol* 2010; 5: 607–615
- Poulsom R, Little MH. Parietal epithelial cells regenerate podocytes. *J Am Soc Nephrol* 2009; 20: 231–233
- Smeets B, Angelotti ML, Rizzo P *et al.* Renal progenitor cells contribute to hyperplastic lesions of podocytopathies and crescentic glomerulonephritis. *J Am Soc Nephrol* 2009; 20: 2593–2603
- Ray PE, Hu CA. Advances in our understanding of the pathogenesis of HIV-1 associated nephropathy in children. *Future Virol* 2011; 6: 883–894
- Zhong J, Zuo Y, Ma J *et al.* Expression of HIV-1 genes in podocytes alone can lead to the full spectrum of HIV-1-associated nephropathy. *Kidney Int* 2005; 68: 1048–1060
- Ray PE, Liu XH, Robinson LR *et al.* A novel HIV-1 transgenic rat model of childhood HIV-1-associated nephropathy. *Kidney Int* 2003; 63: 2242–2253
- Wharram BL, Goyal M, Wiggins JE *et al.* Podocyte depletion causes glomerulosclerosis: diphtheria toxin-induced podocyte depletion in rats expressing human diphtheria toxin receptor transgene. *J Am Soc Nephrol* 2005; 16: 2941–2952
- Pollak MR, Genovese G, Friedman DJ. APOL1 and kidney disease. *Curr Opin Nephrol Hypertens* 2012; 21: 179–182
- Kopp JB, Nelson GW, Sampath K *et al.* APOL1 genetic variants in focal segmental glomerulosclerosis and HIV-associated nephropathy. *J Am Soc Nephrol* 2011; 22: 2129–2137
- Behar DM, Kedem E, Rosset S *et al.* Absence of APOL1 risk variants protects against HIV-associated nephropathy in the Ethiopian population. *Am J Nephrol* 2011; 34: 452–459
- Fine DM, Wasser WG, Estrella MM *et al.* APOL1 risk variants predict histopathology and progression to ESRD in HIV-related kidney disease. *J Am Soc Nephrol* 2012; 23: 343–350
- Madhavan SM, O'Toole JF, Konieczkowski M *et al.* APOL1 localization in normal kidney and nondiabetic kidney disease. *J Am Soc Nephrol* 2011; 22: 2119–2128

Received for publication: 13.2.2012; Accepted in revised form: 5.3.2012