

*Original Article***Focal glomerulosclerosis in the remnant kidney model—an inflammatory disease mediated by cytokines**Brigitte Schiller<sup>1</sup> and John Moran<sup>2</sup><sup>1</sup>Section of Nephrology, Rush Presbyterian St Luke's Medical Center, Chicago and <sup>2</sup>Renal Division, Baxter Healthcare Corporation, McGaw Park, IL, USA**Abstract**

**Background.** The mechanism of progression of established renal disease remains unclear. While a low protein diet slows this progression, the role of cytokines in this process has been little investigated.

**Methods.** We investigated cytokine expression by Northern blot and immunohistochemistry in two groups of 5/6 nephrectomized rats (5/6 Nx) fed a normal (24%) or low (6%) protein diet and compared them with sham operated controls.

**Results.** The rats on 6% protein diet had significantly less focal glomerulosclerosis (FGS) ( $17.4 \pm 4.4$  vs  $27.4 \pm 8.8\%$ ,  $P < 0.05$ ) and global sclerosis (GGS) after 7 weeks ( $0.4 \pm 0.8$  vs  $3.5 \pm 2.1\%$  of glomeruli  $P < 0.05$ ). Both experimental groups showed three times control levels of MCP-1 expression after 2 weeks. However in the 5/6 Nx 6% protein group the expression decreased at 4 weeks (1.5 times controls) and reached control levels after 7 weeks. In contrast, the 5/6 Nx 24% protein group exhibited a further marked increase after 4 weeks (5.6 times controls) and was still two-fold higher after 7 weeks. TGF- $\beta$  expression was modestly but consistently increased at all time points (120–160% of controls), with no difference between the two study groups. Neither IL-1 $\beta$  or TNF- $\alpha$  was detectable at any time. Immunohistochemistry demonstrated TGF- $\beta$  intracellularly in distal tubular cells in both experimental and control animals, while MCP-1 protein was found in the area of FGS and in the apical pole of distal tubular cells in both experimental groups. Glomerular and interstitial ED1 positive cells were significantly increased after four weeks in the 5/6 Nx 24% protein group ( $P < 0.05$ ).

**Conclusions.** A 'mechanical' injury to the kidney clearly results in an inflammatory response associated with the upregulation of MCP-1. A low protein diet modulates the expression of MCP-1 and improves the morphological sequelae seen after renal ablation.

**Key words:** Growth factors; monocyte chemoattractant protein 1; remnant kidney model; transforming growth factor- $\beta$

**Introduction**

Glomerulosclerosis is the characteristic pathological process by which a variety of different kidney diseases progress to end-stage renal disease. Various pathogenetic mechanisms have been proposed, including haemodynamic or permselectivity changes, activation of coagulation, glomerular hypertrophy, disordered lipid metabolism, mesangial overload, proteinuria and the protein content of the diet [1].

It has become evident that parenchymal kidney cells are able to produce a variety of mediators, including cytokines [2–5]. Cytokines act in both a paracrine and autocrine fashion and are therefore able to induce a medley of reactions involving not only the initiatory cell but also its neighbours. Cytokines are also produced by infiltrating cells, including monocytes and lymphocytes, which are routinely found in the interstitium of damaged kidneys [6,7] and whose presence has prognostic implications [8].

Interest has focused on transforming growth factor- $\beta$  (TGF- $\beta$ ), which has been found in several models of experimental glomerulonephritis and glomerulosclerosis [9–12]. TGF- $\beta$  is critical in wound healing [13] and has been thought to play a key role in the accumulation of extracellular matrix (ECM) within the glomerulus and the interstitium, ultimately leading to the destruction of the tissue architecture and thereby to irreversible loss of renal function [14]. Indeed interventions directed to limiting TGF- $\beta$  effects such as the administration of antibody to TGF- $\beta$  [15], decorin [16] or a low protein diet [17–19] resulted in improved outcomes in various models.

Monocytes/macrophages are frequently seen in clinical as well as experimental glomerulonephritis and are believed to participate in its pathogenesis by producing a number of inflammatory mediators, including oxygen radicals, prostaglandins and cytokines [20–22].

Correspondence and offprint requests to: Dr Brigitte Schiller, Section of Nephrology, University of Chicago, 5841 South Maryland Ave, Room S-511, MC 5100, Chicago, IL 60637, USA.

Glomerular macrophage infiltration has generally been assumed to be harmful [23].

Chemokines, a group of cytokines which act as chemoattractants for neutrophils and monocytes, may be involved in the localisation of these infiltrating cells during glomerular inflammation. Monocyte chemoattractant protein 1 (MCP-1) both attracts and activates monocytes, and is produced by a variety of cells either constitutively or after stimulation, including monocytes, endothelial cells, smooth muscle cells and mesangial cells [24]. MCP-1 has also been found in human atherosclerotic plaques [25] and may therefore participate in the pathogenesis of atherosclerosis, a process to which glomerulosclerosis has been likened [26]. The data on MCP-1 in different models of kidney disease are suggestive of a functional role of this chemokine in renal injury [27].

The remnant kidney model, a surgically induced injury, serves as a model of progressive FGS leading to uraemia and has long been considered to be the prototype of the adverse effects of hyperfiltration [28]. The beneficial effect of a low protein diet on the histological outcome in several animal models has been attributed to the decreased adaptive hyperfiltration and haemodynamic changes in the remaining intact nephrons [29], thereby ameliorating the sequelae of renal ablation and preventing the progression of renal disease.

We studied cytokine expression in the whole kidney after renal ablation (5/6 nephrectomy) in rats fed with either a normal (24% protein) or low protein (6%) diet to see whether a low protein diet modulated cytokine expression in this model.

## Material and methods

### *5/6 Nephrectomy and evaluation*

Thirty Sprague-Dawley rats (Harlan, WI) weighing 240–280 underwent 5/6 nephrectomy by right uninephrectomy and microsurgical ligation of two branches of the left renal artery under pentobarbital anaesthesia (Nembutal, Abbott, IL, 4.5 mg/100 g body weight). 18 sham-operated rats served as controls. The animals were fed with either a normal (24%) or low (6%) protein diet (Teklad, Madison, WI); the diets were isocaloric and did not differ in electrolyte, fat or vitamin content. The animals were killed 2, 4 and 7 weeks after surgery; they were starved prior to killing and 24 h urine samples collected for measurement of proteinuria and of GFR by creatinine clearance. Creatinine and total protein in serum and urine were measured on a Boehringer Mannheim/Hitachi 704 autoanalyser.

### *Killing and RNA extraction*

The rats were anaesthetized with methoxyflurane (Pitman-Moore, Mundelein, IL) and killed by exsanguination. In order to remove circulating cells the kidney was perfused *in situ* with 30–40 ml of ice-cold 0.9% saline until it was macroscopically blood free. After manual removal of the capsule the intact part of the kidney was separated from the necrotic piece with a wide macroscopic margin. A small piece

of the remnant kidney was fixed in paraformaldehyde-lysine-periodic acid [30] for histology, and another snap frozen for immunohistochemistry. The remaining part was snap frozen and stored at  $-70^{\circ}\text{C}$  until further processing for RNA extraction.

The remnant/sham kidney was wrapped in aluminium foil and pulverised with a hammer. The material was immediately transferred into cold RNazol (Cinna/Biotech, Friendswoods, TX) and homogenized with a Polytron (Brinkman Instruments) for 10–20 s. RNA was isolated according to the guanidinium thiocyanate method with chloroform extraction, isopropyl alcohol precipitation, and ethanol purification [31]. The RNA pellets were stored at  $-20^{\circ}\text{C}$  in 3 M sodium acetate and ethanol.

### *Northern blot hybridization*

RNA samples were checked for intact RNA by gel electrophoresis, and intact samples from 3–6 rats/group were pooled after measurement of the OD at 260 nm. 30  $\mu\text{g}$  of pooled RNA was run on a 1% agarose gel containing 2.2 M formaldehyde. Equal loading was verified by ethidium bromide staining of the 18S and 28S band. RNA was transferred by vacuum blot (Vacugene XL, Pharmacia, Uppsala, Sweden) onto a nylon membrane (Hybond-N, Amersham, Arlington Heights, IL). The blots were baked for 1–2 h at  $80^{\circ}\text{C}$ .

The following cDNAs were used for hybridization: a 1.2 kb *PstI/SacI* fragment of human IL-1b (provided by Dr C. Dinarello, Tufts New England Medical Center, Boston, MA), a 1.4 kb *EcoRI* fragment for sheep TNF- $\alpha$  (provided by Dr P. Maples, Baxter Healthcare, Round Lake, IL), a 1 kb *HindIII/XbaI* fragment of rat TGF- $\beta$  (provided by Dr S. W. Qian, NCI/NIH, Bethesda, MD), a 655 bp *EcoRI* fragment of rat MCP-1 (provided by Dr T. Yoshimura, NCI/FCRDC, Frederick, MD). A 1.3 kb *EcoRI* fragment of rat GAPDH [32] (provided by M. Loudovaris, WEHI, Melbourne, Australia) served as internal standards. All probes were labelled by the oligoprimer technique (Pharmacia) with [ $^{32}\text{P}$ ] dCTP obtaining a specific activity of up to  $1 \times 10^9$  CPM/ $\mu\text{g}$  DNA. The blots were hybridized overnight (16–20 h) at  $45^{\circ}\text{C}$  in a hybridization buffer containing  $6 \times$  SSPE,  $5 \times$  Denhardt's reagent, 0.5% SDS and 50% formamide. Posthybridization washes were performed  $2 \times 10$  min in  $2 \times$  SSPE/0.1% SDS at  $25^{\circ}\text{C}$ ,  $2 \times 30$  min in  $1 \times$  SSPE/0.5% SDS at  $45^{\circ}\text{C}$ . In some cases a high stringency wash was needed in  $0.1 \times$  SSPE/0.5% SDS at  $45$ – $60^{\circ}\text{C}$  for 30–120 min. Autoradiography was performed at  $-70^{\circ}\text{C}$  with intensifying screens for 24 h to 5 days. In all experiments RNA from a murine monocyte cell line (P338) (ATCC, Bethesda, MD) stimulated with LPS was included as a positive control. The filters were rehybridized with GAPDH to adjust for differences in loading and transfer. Autoradiographs were analysed with computer assisted densitometry using an Image Analysis Program (Quantimet 570 C, Leica) running Q Windows in order to determine the grey level and area of the bands. Cytokine expression level was normalised to that of the 'housekeeping' genes and relative values were obtained by setting the appropriate control group at one. Two analyses per cytokine and housekeeping gene were performed and the mean is given as the result.

### *Light microscopy*

Paraffin embedded kidney sections were stained with PAS. All glomeruli were counted and assessed for the presence of segmental or global sclerosis. FGS and GGS was defined as the accumulation of acellular PAS-positive material with

collapse of capillary loops in part of the glomerulus or the whole glomerulus respectively. Analysis was done in a blind fashion by counting at least 250 glomeruli per group (Figure 1A–C).

### Immunohistochemistry

In order to demonstrate the cytokines detected in Northern blots immunohistochemistry was performed with a polyclonal rabbit anti-LC antibody which detects intracellular TGF- $\beta$  (1:200) [33] (kindly provided by Dr K. C. Flanders, NCI/NIH, Bethesda, MD) and a polyclonal rabbit anti-rat MCP-1 antibody (1:200) (kindly provided by Dr T. Yoshimura) by using a modified four layer technique of alkaline phosphatase/anti-alkaline phosphatase staining [34]. PLP fixed, paraffin embedded midcoronal sections were deparaffinised with xylene and rehydrated with a series of alcohols. Sections were incubated with 1 mg/ml bovine testicular hyaluronidase (Sigma, St Louis, MO) in 0.1 M sodium acetate/0.85% NaCl, pH 5.5 for 30 min at 37°C. After rinsing in TBS/0.1% BSA non-specific staining was blocked by incubation in normal goat serum (Kirkegaard and Perry, Gaithersburg, MD) for 30 min at 25°C. The primary antibody was applied and was incubated at 4°C overnight. Controls were incubated with a non-immune rabbit IgG preparation in the same dilution. After washing in TBS/0.1% BSA the second antibody, alkaline-phosphatase linked (1:50) was added to sections, followed by an anti-alkaline phosphatase (1:50) for 1 h incubation each at 25°C. Chromogen DAB (diaminobenzidine) (Vector, Burlingame, CA) was added and colour development was monitored by microscopy.

For staining of macrophages a mouse monoclonal ED1 antibody (Serotec, Oxford, UK) was used as described above using a peroxidase system in snap frozen sections postfixed in normal buffered formalin (Kirkegaard and Perry, Gaithersburg, MD) with the following incubations: rabbit serum, ED1 (1:50, pre-absorbed with rat serum), rabbit-anti-mouse peroxidase labelled IgG (Dako 1:50), mouse PAP (Dako 1:50) and DAB as chromogen.

Sections were counterstained with hematoxylin. TGF- $\beta$  and MCP-1 staining was assessed only for localisation of the protein, ED1 positive cells were quantitated by counting an average of 100 glomeruli and 36 high power fields per group (in at least three animals).

### Statistical analysis

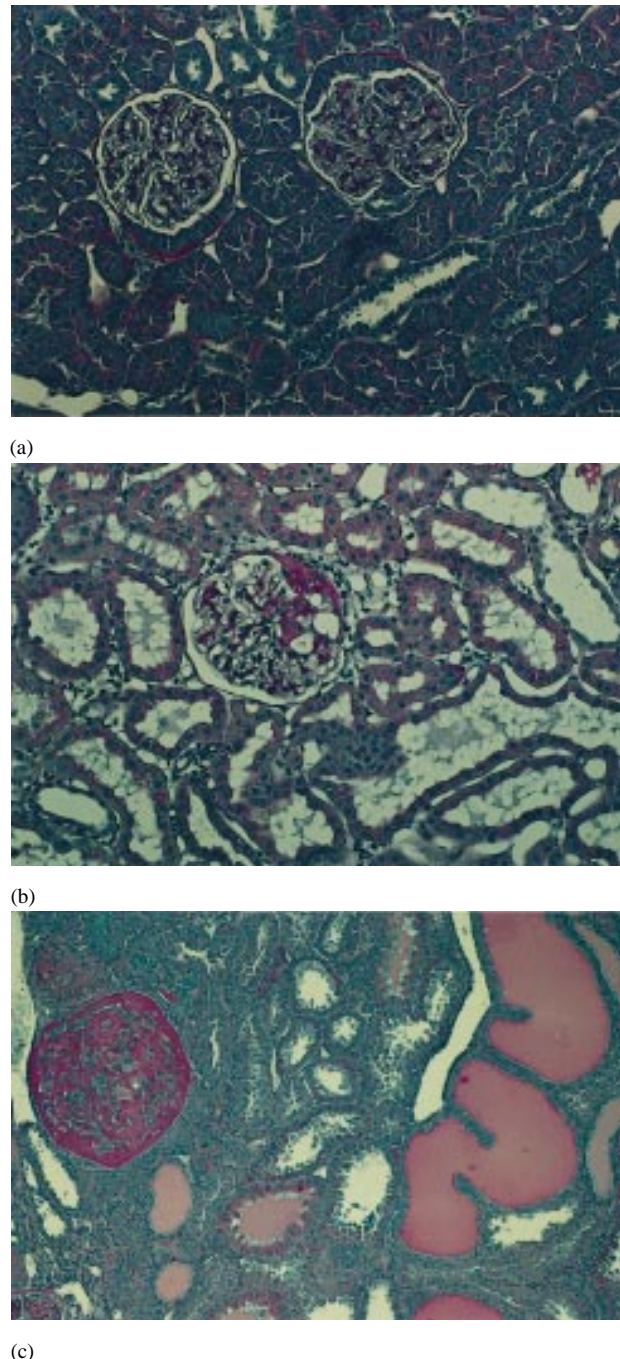
All statistical analyses were performed using JMP version 3.0 (SAS Institute, Cary, NC). Statistical comparisons were performed with the Tukey-Kramer's HSD test. A  $P$ -value of  $<0.05$  was considered to be significant.

## Results

### Clinicopathological parameters

After 5/6 nephrectomy the rats developed progressive renal disease within two weeks. In the group fed with a 24% protein diet 2/16 rats were found dead before completing the study period of 7 weeks, while all rats survived in the 6% protein group.

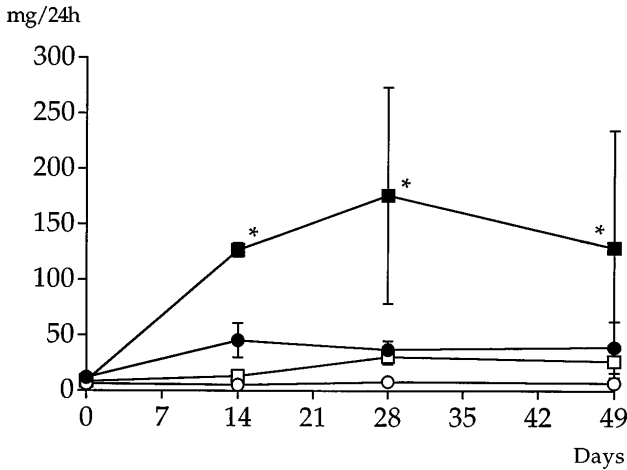
The 6% protein group showed significantly less proteinuria at all times ( $P < 0.05$ ) (Figure 2). Both groups showed a significant decline in GFR two weeks after



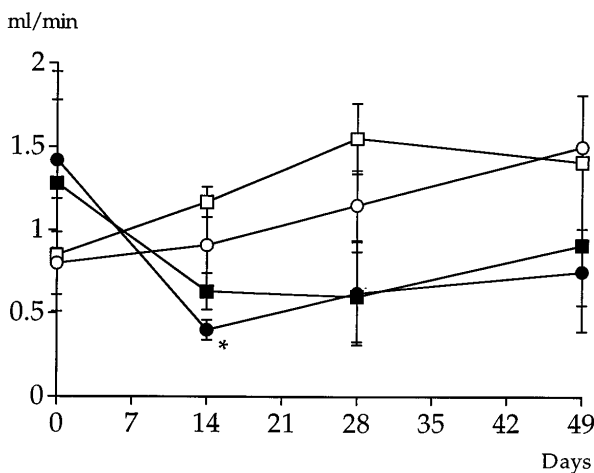
**Fig. 1.** Typical histological findings 7 weeks after nephrectomy. Sham control on a 24% diet (a). Focal glomerular sclerosis (b) and global sclerosis (c) in a 5/6 Nx 24% protein animal. In FGS microaneurysms are characteristic; atrophic tubules and protein casts are frequently found.

surgery which was significantly lower in the 6% group ( $P < 0.05$ ) (Figure 3). There was no difference in GFR between the two groups during the following study period. It should be noted that these measurements did not address the question of the 'functional' lowering of the GFR seen with a low protein intake.

Focal and global glomerulosclerosis was significantly



**Fig. 2.** Time course of proteinuria after renal ablation. & 5/6 Nx 24% protein, § 5/6 Nx 6% protein, % Sham 24% protein, # Sham 6% protein. \* $P < 0.05$ , 5/6 Nx 24% protein group compared to 5/6 Nx 6% protein.



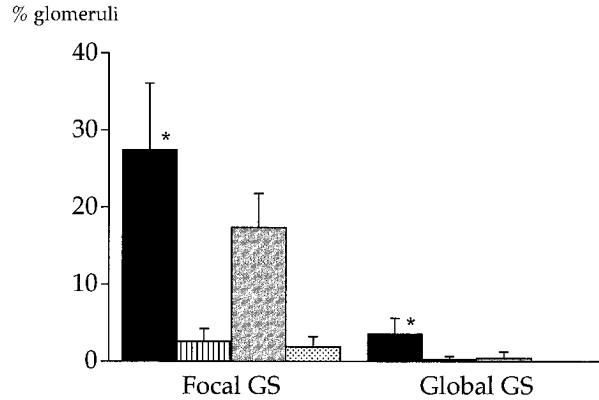
**Fig. 3.** GFR as measured by creatinine clearance in 5/6 nephrectomized and sham operated animals. & 5/6 Nx 24% protein, § 5/6 Nx 6% protein, % Sham 24% protein, # Sham 6% protein. \* $P < 0.05$ , 5/6 Nx 24% protein group compared to 5/6 Nx 6% protein.

reduced in the 6% group after seven weeks ( $P < 0.05$ ) (Figure 4).

#### Cytokine expression

Il-1b and TNF-a could not be detected by Northern blot either in 5/6 nephrectomized or in control rats. However TGF-b and MCP-1 were found to be constitutively expressed in normal kidneys. Expression in whole kidneys from 5/6 nephrectomized rats was found to be different from the controls.

MCP-1 expression differed markedly in the two nephrectomized groups. Both groups exhibited a 3-fold upregulation of MCP-1 expression 2 weeks after surgery. However after 4 weeks there was a different result in the two groups. Expression continued to rise in the 24% protein group to 5.6-fold after 4 weeks and remained twice control levels even after 7 weeks. In



**Fig. 4.** Quantitative analysis of glomerular changes in the remnant kidney model after 7 weeks. The 24% protein 5/6 Nx group (black bars) had a significantly increased number of glomeruli exhibiting FGS and GGS when compared to the 5/6 Nx 6% protein group (gray bars). Both groups were significantly different from their sham control group (Sham 24%—striped bars, sham 6%—dotted bar).

contrast the 6% protein group showed a decline of MCP-1 expression after 4 weeks to only 1.5-fold of controls and reached control levels after 7 weeks (Figure 5).

In contrast, TGF-b was only modestly upregulated in 5/6 nephrectomized rats and did not show differences between the low and normal protein diet group. Both groups exhibited a consistent increase of between 120 and 160% compared to controls (Figure 6).

#### Immunohistochemistry

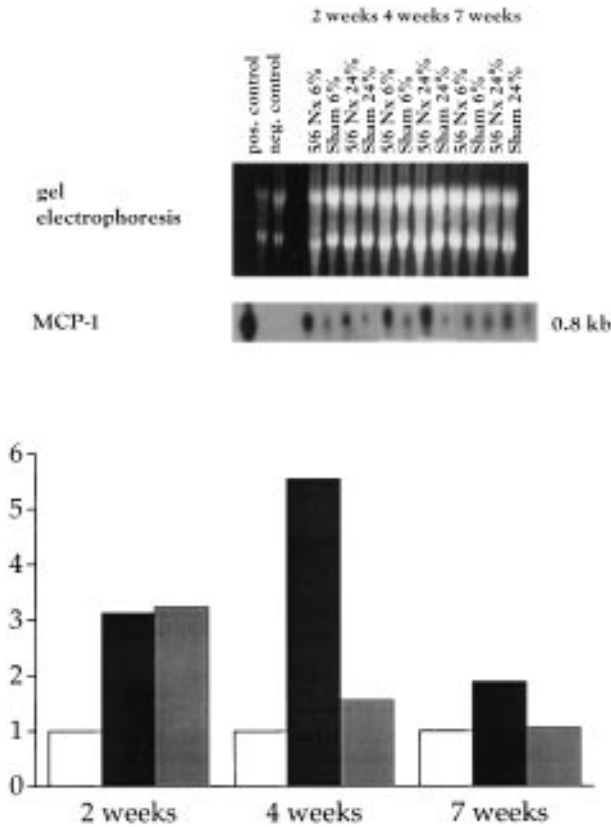
MCP-1 was detected at the apical poles of distal tubular cells as well as in the focal sclerotic areas of the glomeruli of 5/6 nephrectomized rats (Figure 7). It was not detected in sham-operated rats.

TGF-b staining was found to be positive exclusively in distal tubules in the region of the corticomedullary junction of both 5/6 Nx and sham operated rats. It showed a clear intracellular pattern (Figure 8a). All glomeruli were negative, even those with focal or global sclerosis (Figure 8b).

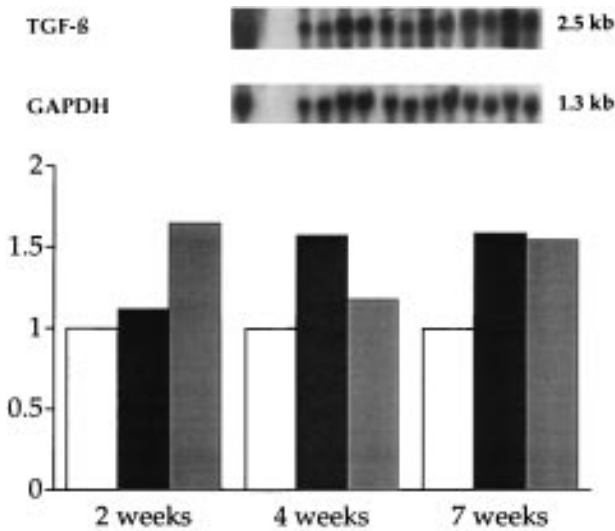
Staining with ED1 for monocyte/macrophages four weeks after surgery showed accumulation of positive cells in both 5/6 Nx groups, with a significantly increased number of ED1 positive cells within the glomerulus and the interstitial area in the 24% group compared to the 6% group (Figure 9a). Both 5/6 nephrectomized groups showed significantly more ED1 positive cells when compared to controls. Figure 9a and b show typical immunohistochemical findings.

#### Discussion

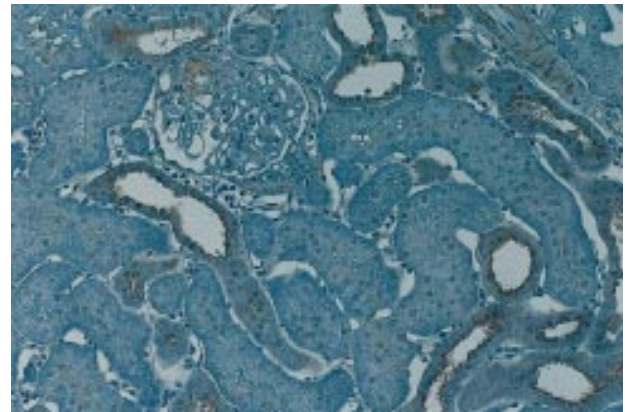
Reduction of renal mass is one of the most widely used approaches to induce renal failure and often used as a model to study the events of uraemia. 'Compensatory' haemodynamic adaptation processes in the remaining nephrons leading to increased glomer-



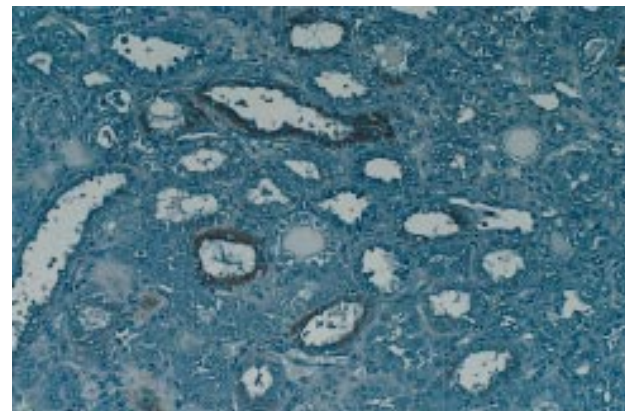
**Fig. 5.** MCP-1 expression as demonstrated in autoradiographs after rehybridization of the TGF- $\beta$  blots. Gel electrophoresis of pooled RNA from 4–6 rats is shown. GAPDH as demonstrated in Figure 6 served as ‘housekeeping gene’. Cytokine expression was normalized to GAPDH and relative values are given by setting the sham controls at 1. In order to simplify the graph only one open bar is demonstrated; no difference was found between sham controls on 24 or 6% protein diet. Black bars; 5/6 Nx 24% protein, gray bars; 5/6 Nx 6% protein, open bars; sham controls.



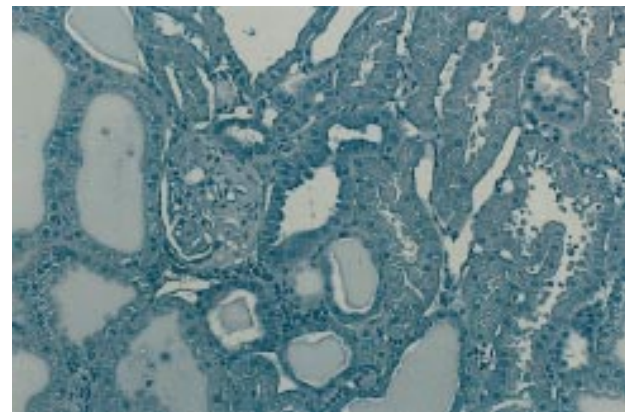
**Fig. 6.** TGF- $\beta$  expression in whole kidneys from 5/6 Nx and sham controls measured by Northern blot of total RNA from the remnant kidney. Autoradiographs are shown including the ‘housekeeping gene’ GAPDH. Black bars; 5/6 Nx 24% protein, gray bars; 5/6 Nx 6% protein, open bars; sham controls.



**Fig. 7.** MCP-1 immunohistochemical staining in a 5/6 Nx rat on a 24% protein diet. Positive staining within the sclerotic glomerular area and in the apical poles of tubular cells.



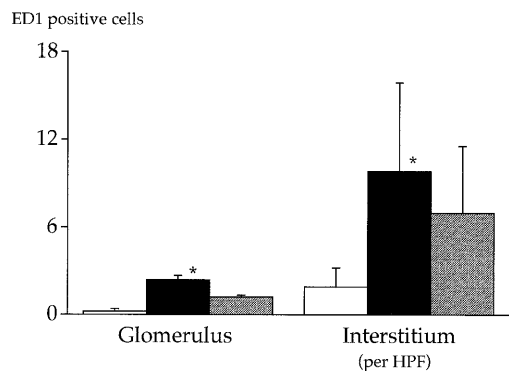
(a)



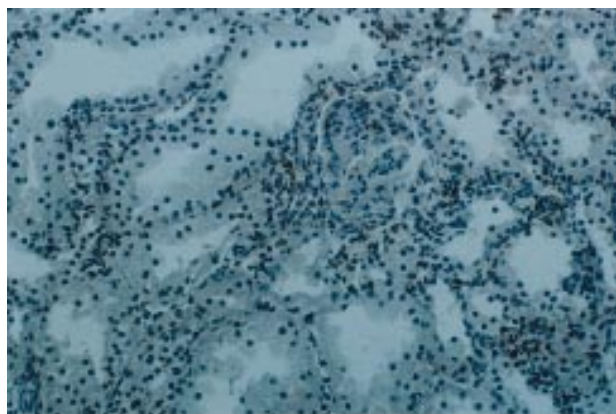
(b)

**Fig. 8.** TGF- $\beta$  staining was exclusively found in distal tubular cells at the corticomedullary junction as shown in a 5/6 Nx rat on 24% protein (a). Glomerular and tubular cells within the cortex remained negative (b).

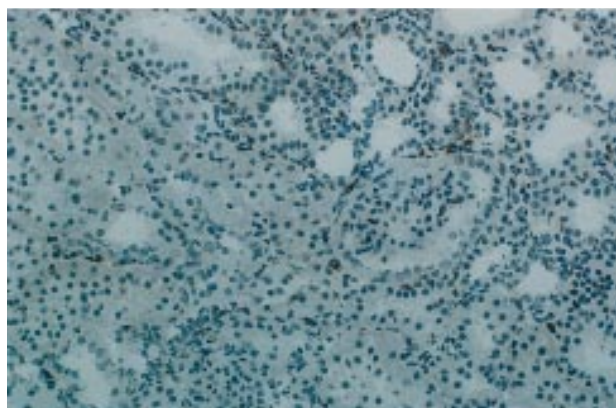
ular pressure and flow have been proposed as the mechanism of residual nephron destruction [35]. By reducing the protein content of the diet the morphology after one and one-third nephrectomy was found to be improved and the progression of disease to be retarded



(a)



(b)



(c)

**Fig. 9.** (a) Distribution of ED1 positive cells in glomerular and interstitial areas after 4 weeks showed significantly more ED1 positive cells ( $P < 0.05$ ) in glomeruli and interstitium of the 5/6 Nx 24% group (black bars) compared to 5/6 Nx 6% group (gray bars) and sham controls 24% group (open bar). Typical immunohistochemical findings are demonstrated in a 24% rat (b) and in a 6% rat (c).

[36]. Consequently the chronic administration of a normal/high protein diet leading to hyperfiltration and glomerular hypertrophy was hypothesized to be the responsible mechanism resulting in progressive glomerular sclerosis not only after renal ablation, but also in other kidney diseases and in aging [29].

Our data provide evidence that a low protein diet influences the expression pattern of MCP-1 in the remnant kidney. As in previous studies [36] the low protein diet group showed a significant decrease of FGS 7 weeks after ablation. MCP-1 expression was 3-fold upregulated 2 weeks after surgery independent of dietary protein, indicating an early response to ablation. Two weeks after extensive reduction of functioning renal tissue a local inflammatory response is present, possibly representing an attempt at repair. Dependent on the protein content of the diet, however, we found a further increase in MCP-1 expression only in the 24% protein 5/6 Nx group while the 6% protein 5/6 Nx group decreased to only 1.5-fold control levels after 4 weeks. This tendency was further emphasized by an expression of MCP-1 comparable to normal controls in the 6% protein 5/6 Nx group after 7 weeks, when the 24% protein 5/6 Nx group still exhibited an almost 2-fold increase.

Since the renal ablation model is surgically induced, it is interesting to find an upregulation of a pro-inflammatory cytokine such as MCP-1 in the remaining intact tissue. Within the remnant kidney an immunological process is initiated and maintained in normal undamaged tissue. The inflammatory reaction within the kidney was much more pronounced in the group fed with a normal protein diet. Floege *et al.* (1992) demonstrated in the remnant kidney early glomerular cell proliferation and PDGF expression preceding the development of glomerulosclerosis. Furthermore they documented continuous macrophage infiltration starting as early as 2 weeks after ablation and reaching a maximum after 10 weeks [37]. Our findings suggest that MCP-1 contributes to macrophage infiltration in this model. We found MCP-1 protein in the intra-glomerular lesion as well as the apical pole of distal tubular cells. It is possible that this finding reflects uptake by the distal tubular cells of glomerular-produced MCP-1 from the glomerular filtrate. This may well represent a route of communication between glomerular, tubular and interstitial structures and ultimately contribute to the progressive destructive processes after the initial injury. There was a significant increase of ED1 positive cells in the interstitial as well as the glomerular area in the 5/6 Nx group fed with a normal protein diet compared to the 6% protein group. Glomerular macrophage influx has been found to be a determinant of mesangial matrix expansion and the development of adhesions in this model [38], indicating the importance of these multipotential cells in the development of FGS.

After acute renal ischemia in the rat an upregulation of the MCP-1 gene has been detected in the renal cortex for up to 96 h [39]. Similarly, MCP-1 expression has been demonstrated in proximal tubular cells after unilateral ureteral obstruction [40]. Haemodynamic or pressure induced injury therefore induces an inflammatory response within the kidney representing a cellular/molecular signal of these processes. A possible link may be free oxygen radicals—generated in injured tissue—which have been postulated to act as second

messengers for MCP-1 expression in mesangial cells [41].

TGF- $\beta$  was found to be only modestly increased in both groups after renal ablation over the whole study period. TGF- $\beta$  with its multiple effects on ECM accumulation and its role in wound healing [13] has lately been focused upon as the major cytokine leading to glomerulosclerosis [42]. Data from the unilateral ureteral obstruction model indicate that the TGF- $\beta$  expression is mediated by angiotensin II, a possible link between the consequent alterations in pressure and fibrosis development [43]. However, our data demonstrate that variations in TGF- $\beta$  expression do not explain the better outcome seen in rats on a low protein diet. It rather suggests that the mutual amplification of different cytokines may represent the crucial mechanism in the progression of disease [44]. Consistent with this hypothesis are immunohistochemical findings in the remnant kidney model which showed a mosaic of cytokines appearing after the injury [45].

Our data confirm the benefit of a low protein diet in the remnant kidney model. While this was thought primarily to be attributed to the ameliorated haemodynamic adaptation [29], we would like to propose a further hypothesis. Our data suggest that the low protein diet may have produced a better outcome by modulating MCP-1 expression and thereby reducing the numbers of monocyte/macrophages after injury. The altered glomerular/tubular pressures may directly affect the expression and release of mediators critical to the outcome. Rosenberg demonstrated lower renin RNA expression in uninephrectomised rats fed with a low protein diet [46]. There is evidence that dietary intake also modulates the glomerular eicosanoid production [47]. Furthermore a low protein diet has been shown to be beneficial in tubulointerstitial disease in humans [48]. In experimental tubulointerstitial disease a low protein diet exhibited a protective effect by inhibiting the cell-mediated immune response suggesting a different mechanism to retard progression of renal disease [49]. Finally Eddy showed that a low protein diet significantly decreased the interstitial fibrosis in experimental nephrotic syndrome [19] a process which may well be mediated by chemokines such as MCP-1.

Comparison to other organs reveals interesting parallels. In bleomycin induced lung fibrosis MCP-1 and TGF- $\beta$  appear to be key among the mechanisms involved after injury [50,51]. Data are emerging indicating a common pathway of fibrosis formation which may help us find new therapeutic approaches [52]. The kidney reacts to different types of injury with an inflammatory response through its ability to express mediators such as MCP-1. The ultimate outcome—persistence or resolution of inflammation—seems related to the pattern of cytokine expression. The analogy of wound healing by primary or secondary intention is attractive.

*Acknowledgements.* The authors wish to acknowledge the expert technical assistance of Mike DeLeo and Emily Warren. This study

was supported by a grant from the Deutsche Forschungsgemeinschaft (Schi 321/1) and by a grant from the Renal Division, Baxter Healthcare Corporation, McGaw Park, IL, USA. Part of this work has been presented at the 1994 Annual Meeting of the Australian and New Zealand Society of Nephrology and published in abstract form in *Kidney Int*, 1994; 46: 938.

## References

1. Klahr S, Schreiner G, Ichikawa I. The progression of renal disease. *N Engl J Med* 1988; 318: 1657–1666
2. Lovett DH, Larsen A. Cell cycle-dependent interleukin 1 gene expression by cultured glomerular mesangial cells. *J Immunol* 1988; 134: 1796–1801
3. Abboud HE, Poptic E, DiCorleto P. Production of platelet-derived growth factor-like protein by rat mesangial cells in culture. *J Clin Invest* 1987; 80: 675–683
4. McKay K, Striker LJ, Stauffer JW, Doi T, Agodoa LY, Striker GE. Transforming growth factor- $\beta$ . *J Clin Invest* 1989; 83: 1160–1167
5. Frank J, Engler-Blum G, Rodemann HP, Müller GA. Human renal tubular cells as a cytokine source: PDGF- $\beta$ , GM-CSF and IL-6 mRNA expression *in vitro*. *Exp Nephrol* 1993; 1: 26–35
6. Hooke DH, Gee DC, Atkins RC. Leucocyte analysis using monoclonal antibodies in human glomerulonephritis. *Kidney Int* 1987; 31: 964–973
7. Markovic-Lipkovski J, Müller CA, Risler T, Bohle A, Müller GA. Glomerular and interstitial infiltrates of mononuclear leukocytes in glomerulonephritis. *Nephrol Dial Transplant* 1990; 5: 10–17
8. Bohle A, Mackensen-Haen S, von Gise H, Grund KE, Wehrmann M, Batz C, Bogenschütz O, Schmitt H, Nagy J, Müller C, Müller G. The consequences of tubulo-interstitial changes for renal function in glomerulopathies. A morphometric and cytological analysis. *Path Res Pract* 1990; 186: 135–144
9. Okuda S, Languino LR, Ruoslahti E, Border WA. Elevated expression of transforming growth factor- $\beta$  and proteoglycan production in experimental glomerulonephritis. *J Clin Invest* 1990; 86: 453–462
10. Ding G, Pesek-Diamond I, Diamond J. Cholesterol, macrophages, and gene expression of TGF- $\beta$  and fibronectin during nephrosis. *Am J Physiol* 1993; 264: F577–F584
11. Nakamura T, Ebihara I, Fukui M *et al*. Messenger RNA expression for growth factors in glomeruli from focal glomerular sclerosis. *Clin Immunol Immunopathol* 1993; 66: 33–42
12. Tamaki K, Okuda S, Takashi A *et al*. TGF- $\beta$ 1 in glomerulosclerosis and interstitial fibrosis of adriamycin nephropathy. *Kidney Int* 1994; 45: 525–536
13. Sporn MB, Roberts AB. Peptide growth factors and inflammation, tissue repair and cancer. *J Clin Invest* 1986; 78: 329–332
14. Border W. Transforming growth factor- $\beta$  and the pathogenesis of glomerular diseases. *Curr Opin Nephrol Hypertens* 1994; 3: 54–58
15. Border WA, Okuda S, Languino LR, Sporn MB, Ruoslahti E. Suppression of experimental glomerulonephritis by antiserum against transforming growth factor  $\beta$ 1. *Nature* 1990; 346: 371–374
16. Border WA, Noble NA, Yamamoto T *et al*. Natural inhibitor of transforming growth factor- $\beta$  protects against scarring in experimental kidney disease. *Nature* 1992; 360: 361–363
17. Okuda S, Nakamura T, Yamamoto T, Ruoslahti E, Border WA. Dietary protein restriction rapidly reduces transforming growth factor  $\beta$ 1 expression in experimental glomerulonephritis. *Proc Natl Acad Sci USA* 1991; 88: 9765–9769
18. Fukui M, Nakamura T, Ebihara I, Nagaoka I, Tomino Y, Koide H. Low protein diet attenuates increased gene expression of platelet-derived growth factor and transforming growth factor- $\beta$  in experimental glomerular sclerosis. *J Lab Clin Med* 1993; 121: 224–234
19. Eddy AA. Protein restriction reduces transforming growth factor- $\beta$  and interstitial fibrosis in nephrotic syndrome. *Am J Physiol* 1994; 266: F884–F893

20. Cattell V. Macrophages in acute glomerular inflammation (editorial review). *Kidney Int* 1994; 45: 945–952
21. Boyce NW, Tipping PG, Holdsworth SR. Glomerular macrophages produce reactive oxygen species in experimental glomerulonephritis. *Kidney Int* 1989; 35: 778–782
22. Nathan CF. Secretory products of macrophages. *J Clin Invest* 1987; 79: 319–326
23. Schreiner GF. The role of macrophages in glomerular injury. *Semin Nephrol* 1991; 11: 268–275
24. Miller MD, Krangel MS. Biology and biochemistry of the chemokines: a family of chemotactic and inflammatory cytokines. *Cr Rev Immunol* 1992; 12: 17–46
25. Nelken NA, Coughlin SR, Gordon D, Valente AJ. Monocyte chemoattractant protein-1 in human atheromatous plaques. *J Clin Invest* 1991; 88: 1121–1125
26. Diamond JR, Karnovsky MJ. Focal and segmental glomerulosclerosis: analogies to atherosclerosis. *Kidney Int* 1988; 33: 917–924
27. Stahl RAK. Chemoattractive cytokines (chemokines) and immune renal injury. *Nephrol Dial Transplant* 1995; 10: 307–309
28. Hostetter TH, Olson JL, Rennke HG, Venkatachalam MA, Brunner BM. Hyperfiltration in remnant nephrons: a potentially adverse response to renal ablation. *Am J Physiol* 1981; 241: F85–F93
29. Brenner BM, Meyer TW, Hostetter TH. Dietary protein intake and the progressive nature of kidney disease: The role of hemodynamically mediated glomerular injury in the pathogenesis of progressive glomerular sclerosis in aging, renal ablation, and intrinsic disease. *New Engl J Med* 1982; 307: 652–659
30. McLean IW, Nakane PK. Periodate-lysine-paraformaldehyde fixative: a new fixative for immunoelectron microscopy. *J Histochem Cytochem* 1974; 22: 1077–1083
31. Chromczynski P, Sacchi N. Single step method of RNA isolation by acid guanidinium thiocyanate-phenol-chloroform extraction. *Anal Biochem* 1987; 162: 156–159
32. Piechaczyk M, Blanchard JM, Marty L, Dani Ch, Panabieres F, El Sabouty S, Fort Ph, Jeanteur Ph. Posttranscriptional regulation of glyceraldehyde-3-phosphate-dehydrogenase gene expression in rat tissues. *Nuc Acid Res* 1984; 12: 6951–6963
33. Flanders KC, Thompson NL, Cissel DS, van Obergher-Schilling E, Baker CC, Kass ME, Ellingsworth LR, Roberts AB, Sporn MB. Transforming growth factor- $\beta$ 1: histochemical localization with antibodies to different epitopes. *J Cell Biol* 1989; 108: 653–660
34. Hancock WW, Becker GJ, Atkins RC. A comparison of fixatives and immunohistochemical techniques for use with monoclonal antibodies to cell surface antigens. *Am J Clin Pathol* 1982; 78: 825–831
35. Hostetter TH, Rennke HG, Brenner BM. Compensatory renal hemodynamic injury: a final common pathway of residual nephron destruction. *Am J Kidney Dis* 1982; 1: 310–314
36. Hostetter TH, Meyer TW, Rennke HG, Brenner BM: Chronic effects of dietary protein in the rat with intact and reduced renal mass. *Kidney Int* 1986; 30: 509–517
37. Floege J, Burns MW, Alpers CE, Yoshimura A, Pritzl P, Gordon K, Seifert RA, Bowen-Pope DF, Couser WG, Johnson RJ. Glomerular cell proliferation and PDGF expression precede glomerulosclerosis in the remnant kidney model. *Kidney Int* 1992; 41: 297–309
38. Van Goor H, Fidler V, Weening JJ, Grond J. Determinants of focal and segmental glomerulosclerosis in the rat after renal ablation. *Lab Invest* 1991; 64: 754–765
39. Safirstein R, Megyesi J, Saggi SJ *et al*. Expression of cytokine-like genes JE and KC is increased during renal ischemia. *Am J Physiol* 1991; 261: F1095–F1101
40. Diamond JR, Kees-Folts D, Ding G, Frye JE, Restrepo NC. Macrophages, monocyte chemoattractant peptide-1 and TGF- $\beta$  in experimental hydronephrosis. *Am J Physiol* 1994; 266: F926–F933
41. Satriano J *et al*. Reactive oxygen species as 2nd messengers for activation of CSF-1 and MCP-1 in mesangial cells. *J Am Soc Nephrol* 1993; 4: 631 (abstract)
42. Border WA, Ruoslahti E. Transforming growth factor- $\beta$  in disease: The dark side of tissue repair. *J Clin Invest* 1992; 90: 1–7
43. Pimentel JL, Sundell CL, Wang S *et al*. Role of angiotensin II in the expression and regulation of transforming growth factor- $\beta$  in obstructive nephropathy. *Kidney Int* 1995; 48: 1233–1246
44. Johnson RJ. Cytokine networks and the pathogenesis of glomerulonephritis. *J Lab Clin Med* 1993; 121: 190–192
45. Muchaneta-Kubara EC, Sayed-Ahmed N, El Nahas AM. Subtotal nephrectomy: a mosaic of growth factors. *Nephrol Dial Transpl* 1995; 10: 320–327
46. Rosenberg ME, Chmielewski D, Hostetter TH. Effect of dietary protein on renin and angiotensinogen gene expression. *J Clin Invest* 1990; 85: 1144–1149
47. Don BR, Blake S, Hutchinson FN, Kaysen GA, Schambelan M. Dietary protein intake modulates glomerular eicosanoid production in the rat. *Am J Physiol* 1989; 256: F711–F718
48. El Nahas AM, Masters-Thomas A, Brady SA, Farrington K, Wilkinson V, Hilson AJ, Varghese Z, Moorhead JF. Selective effect of low protein diets in chronic diseases. *British Med Journal* 1984; 289: 1337–1341
49. Agus D, Mann R, Cohn D *et al*. Inhibitory role of dietary protein restriction on the development and expression of immune-mediated antitubular basement membrane-induced tubulointerstitial nephritis in rats. *J Clin Invest* 1985; 76: 930–936
50. Khalil N, Berenzay O, Sporn MB, Greenberg AH. Macrophage production of transforming growth factor  $\beta$  and fibroblast collagen synthesis in chronic pulmonary inflammation. *J Exp Med* 1989; 131: 836–843
51. Zhang K, Gharace-Kermani M, Jones ML, Warren JS, Phan SH. Lung monocyte chemoattractant protein-1 gene expression in bleomycin-induced pulmonary fibrosis. *J Immunol* 1994; 153: 4733–4741
52. El Nahas AM. Pathways to renal fibrosis. *Exp Nephrol* 1995; 3: 71–75

Received for publication: 4.6.96

Accepted in revised form: 11.10.96